

## Endoscopic assisted suturectomy for primary craniosynostosis in infancy

Ramadan Shamseldien\*, Hedaya Hendam and Abdelhfiz Shehbeldien

<sup>1</sup>Shebin Elkom teaching hospital, Egypt<sup>2</sup>Alazhar university<sup>3</sup>head department of neurosurgery Elshahel teaching hospital

## \*Corresponding author

Ramadan Shamseldien, Shebin Elkom teaching hospital, Egypt, E-mail: ramadanal77@gmail.com

Submitted: 19 Mar 2018; Accepted: 24 Mar 2018; Published: 10 Apr 2018

**Abstract**

**Background:** Multiple procedures have been used for the treatment of craniosynostosis, ranging from simple suturectomy to extensive calvarial vault remodeling. The optimal timing for surgery is still controversial. The goal of therapy is to provide adequate intracranial volume, in addition to an aesthetically almost normal skull shape. Endoscopic synostosis repair described in 1998 by Jimenez and Baron [1]. This technique allows for a less invasive method that can result in excellent longstanding reconstruction of the cranial skeleton. This method is a minimally invasive approach that has less morbidity involved with traditional reconstruction techniques.

**Aim:** Evaluation of early endoscopic suturectomy and its impact on both neurological functions and cosmetic appearance of infants up to 6 months of age suffering primary craniosynostosis.

**Methodology:** This is a prospective analytical study of 50 patients with primary non syndromic craniosynostosis either single suture or multiple sutures, up to sixth months of age; with evident of skull shape deformity and or manifestations of increase intracranial pressure. from; October 2009 to October 2016 were managed by endoscopic assisted suturectomy the approach of Jimenez and Baron, in both Neurosurgery Department Shebin Elkom teaching hospital and Neurosurgery Department in Elshahel teaching hospital. Clinical and radiological follow up for six months postoperative.

**Results:** This is a prospective analytical study of 50 patients with primary craniosynostosis, 28 patients are male and 22 patients are female. The age of patients range from one and half months to sixth months. The majority of cases presented with deformity alone 68%. Other clinical presentations as manifestations of increased intracranial pressure, fits, and delayed milestones plus deformity was 20%, 8%, and 4% respectively. Estimated blood loss, the mean loss was 56cc, minimum 30cc, and maximum was 100cc, with stander deviation  $\pm 18$ cc. The minimum hospital stay was one day and maximum was three days. There is significant change of head shape and head circumference postoperatively this observed by highly significant P value in head circumference ( $< 0.001$ ).

**Conclusion:** Endoscopic assisted suturectomy is minimally invasive approach with a very narrow range of complications, very limited need to blood transfusion and if it occurs, it is small volume in relation to total volume. Very short ICU and hospital stay also decrease the economic load.

**Keywords:** Congenital, Craniosynostosis, Surgical Approaches, Endoscopic Suturectomy

**Introduction**

Craniosynostosis is the premature closure of calvarial sutures. Primary craniosynostosis is due to abnormalities of skull development, whereas secondary craniosynostosis results from failure of brain growth and expansion [2]. It has an estimated frequency of 0.4 of 1000 persons. Approximately 80 to 90% of cases involve isolated suture, in the isolated cases, the sagittal suture is the commonest (55%), followed by the coronal (20%),

lambdoid (5%), and metopic (5%) sutures. The remaining cases are a part of a recognized syndrome such as Crouzon or Apert [3,4]. The fused suture restricts growth of the calvaria, thus leading to a characteristic deformation, each associated with a different type of craniosynostosis. Premature closure of skull sutures is associated with compensatory cranial and facial deformational changes that by 6 months of age often present with changes requiring major reconstructive procedures, so surgeons at many centers favor surgical correction before that age to avoid the morbidity caused by extensive cranial vault remodeling in older children, in addition early intervention improves skull geometry and allows for normal brain

growth [1]. There is a 7% chance of increased intracranial pressure with one suture synostosis and the risk increased when multiple suture is involved. In cases of multiple suture craniosynostosis the incidence of increased intracranial pressure can be as high as 62 % [5]. Commonly, craniosynostosis is present at birth, but it is not always diagnosed when mild. Usually it is diagnosed as a cranial deformity in the first few months of life. The diagnosis relies on physical examination and radiographic studies, including plain radiography and computed tomography (CT). Surgical intervention was not attempted until it was reliably recognized that craniosynostosis could lead to impaired neurological and cognitive growth, blindness, and hydrocephalus [6]. The surgical goal is to increase the intracranial volume, especially under the fused suture, and prevent any long-term complications. Normalization of the calvarial shape successfully achieves this goal [7]. The first surgical treatment of craniosynostosis was undertaken by Lannelongue in 1892, and involved the correction of a sagittal synostosis. Since then, multiple procedures have been used for the treatment of this condition, ranging from simple suturectomies to extensive calvarial vault remodeling [8,9]. The goal of therapy is to provide adequate intracranial volume, in addition to an aesthetically normal skull shape. The surgical options for management of craniosynostosis are, suture release in infancy; operations to correct midface deformities in childhood; and orthognathic surgery in adolescence. The exact timing and sequence of each of the fore mentioned surgical procedures is dependent on both the neurological functions and cosmetic appearance [10]. Jimenez and Barone first described endoscopic synostosis repair in 1998 [1]. This technique allows for a less invasive method that can result in excellent longstanding reconstruction of the cranial skeleton. This method is a minimally invasive approach that has less morbidity involved with traditional reconstructions. Although simple suturectomy and strip craniectomy resulted in excellent outcome in early infancy, these were inadequate approaches for older children with advanced disease [11]. And so this procedure unlikely to ever completely replace standard ones using bicoronal incisions, multiple craniotomies and osteotomies, and plate and screw reconstruction (particularly in children more than 6 months of age), they should be part of the armamentarium of the modern craniofacial surgeon for the treatment of craniosynostosis in the neonatal period [12]. This novel technique composed of simple suturectomy via an endoscopic approach. The success of this approach depends on first, surgery in early life, second, the rapid brain growth would cause expansion of the skull into a normal shape, third in certain cases post-operative helmet. Over all review of their technique from 1999 to 2010 in affected children with a variety of multiple-suture nonsyndromic craniosynostosis demonstrates results superior to results with known invasive procedures. This most recent advancement, founded upon the principles of the natural history and pathophysiology of craniosynostosis, has led to dramatically improved outcomes and has fundamentally changed the treatment of these patients [13].

### Patients and Methods

50 cases of primary craniosynostosis, nonsyndromic either single or multiple sutures, up to sixth months of age; with evident deformity of skull shape and or manifestations of increase intracranial pressure. from; October 2009 to October 2016 were treated by endoscopic assisted suturectomy in both Neurosurgery Department Shebin Elkom teaching hospital and Neurosurgery Department Elshahel teaching Hospital. Patients with secondary craniosynostosis: (e.g., holoprosencephaly, microcephaly, shunted hydrocephalus,

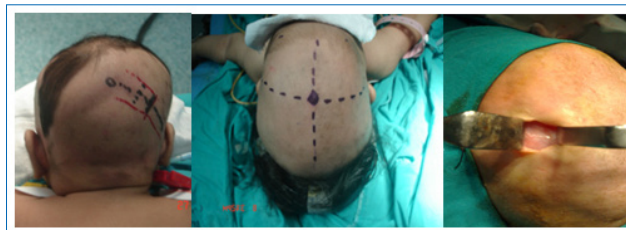encephalocele) were excluded. All the studied cases were subjected to the following management schedule: Detailed history taking ,Full general and neurological examination, plain CT brain with bone window, and three-dimensional reconstruction images of skull and craniofacial bone for detailed and individual suture evaluation, Operative preparation, Surgical procedure utilizing Jimenez and Barone technique.

### Surgical technique: Anesthesia

General anesthesia; / endotracheal intubation; / maintenance by sevoflurane or isoflurane. Monitoring to: conscious level, pulse-oxymetry, capnogram, respiratory movement and rate, ECG and blood pressure. A single preoperative dose of ceftriaxone (500mg) is administered.

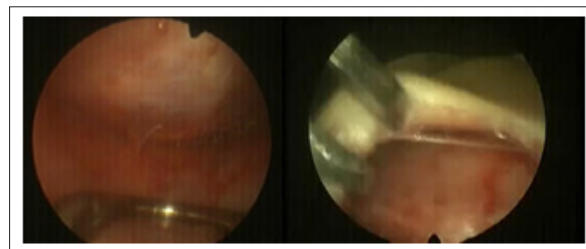
### Operative Steps: Position

Supine in coronal and metopic synostosis, and modified prone position (sphinx position) in sagittal and lambdoid synostosis. The scalp is then scrubbed for 5 minutes with povidone iodine scrub. Povidone iodine paint is then applied. Incisions are marked for the particular repair being performed and 0.25% bupivacaine with 1: 100,000 epinephrine is injected. Warmers are placed under the child. The head is then draped in the standard fashion. **Skin incision;** about two centimeters perpendicular to the middle of suture affected.



### Dissection

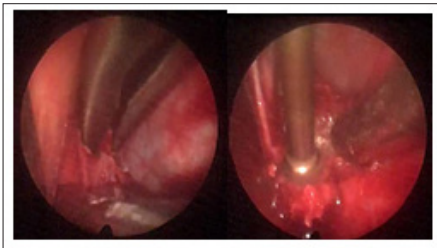
endoscopically assisted by 4mm zero lens galeal dissection done along the whole length of the suture with the proximal portion of adjacent sutures, leaving intact periosteum. The suture line was exposed with its periosteum attachment and he area till the next proximal sutures. Burr hole done just beside suture line on one side by small blade of hudson brace. Craniectomy is widened at this point to the other side of the suture, the endoscope is introduced and blunt dissection of the endosteum from dural attachment at the sutural area along the whole length with the proximal portion of adjacent sutures.



Endoscopic view of suture line before suturectomy

**Craniectomy** using bone nibblers and mayo scissor craniectomy were done with removal of the periosteum attachment to the whole suture in three-centimeter width (one and half cm on either sides of affected suture), with extension of suturectomy to proximal portion of adjacent sutures in case of coronal, metopic and lambdoid. In sagittal synostosis, the width of craniectomy extended to five

centimeters (two and half cm on either side from suture). In the basal part of coronal suture the drill may be used to ensure sphenoid drilling and basal opening the sphenofrontal suture.



Endoscopic view of drilling and bone nibbling

### Closure

After hemostasis with bone waxing and gel foam at sutural area, drain of the wound with nelaton tube, the wound is closed in single layer by absorbable suture polyglactin (e.g. vicryl 2\0) and head covered with tight bandage for 24hs [14].

### Points to be recorded

Starting time, finishing time, operative duration, estimated blood loss, amount of intraoperative blood transfusion, intraoperative complications and body temperature (heat loss).

### Post-operative course

ICU stay period: post-operative hemoglobin and need to blood transfusion and its amount: neurological complications and condition of the wound.

### Follow up

Clinical and radiological follow up.

By using the measuring tap certain indices documented to assess deformity and make baseline for post-operative follow up: Head circumference & Cranial index: The cranial index (CI) represents the ratio of maximum cranial width to maximum cranial length. Children with normal head shape (mesocephalic) have an average CI of 76% to 78%, while dolichocephalic head with CI less than 75%, and brachycephalic head with CI more than 80% [15]. To quantify maximum cranial width, the caliper technique requires the identification of the euryon (the most lateral point on each side of the head). Similarly, the determination of the cranial length requires the identification of the glabella, the most prominent point in the medial sagittal plane between the supraorbital ridges, and the opisthocranium, the most prominent point of the occiput [16].

-Cranial width: euryon to euryon.

-Cranial depth: glabella to Opisthocranium.

-Cranial index: is a proportion of the width of the head to the length of the head.

### Clinical

Patients undergo general and neurological evaluation monthly for six months postoperatively. Cranial indices (head circumference and cranial index) were monthly recorded during the sixth postoperative months.

### Radiological

Craniometric study of 6<sup>th</sup> months follow up CT (cranial index).

Radiological assessment of released suture, as regard recloser

in plain x-ray, and CT bone window, and CT three-dimensional reconstruction.

### Results

This is a prospective analytical study of 50 patients with primary craniosynostosis that fulfill the inclusion criteria, 28 patients are male and 22 patients are female. The age of patients range from one and half months to sixth months. All patients have been treated by endoscopic assisted suturectomy. In this study, 6 cases of studied group show positive consanguinity. Four cases show history of similar family condition. The majority of cases of the studied group presented with deformity alone 68%. Other clinical presentations as manifestations of increased intracranial pressure, fits, and delayed milestones plus deformity was 20%, 8%, and 4% respectively. Manifestations of increased intracranial pressure were in the form of attacks of irritable crying and unexplained attacks of vomiting that push the pediatrician to refer these cases. The recorded deformities, showing that brachycephalic and anterior plagiocephalic deformities were common in female gender 45.5% and 36.4% respectively. While scaphocephalic deformity was common in male gender 50%. The coronal suture synostosis either bilateral or unilateral was common in females. Sagittal suture synostosis was common in males. Also, the most isolated suture synostosis was the sagittal suture (28%), followed by coronal suture (16%) and less frequently isolated sutures were metopic followed by lambdoid. Mean operative time was one and half hour, minimum time was one hour and maximum time two hours, with stander deviation  $\pm$  half an hour. Estimated blood loss the mean loss was 56cc, minimum 30cc, and maximum was 100cc, with stander deviation  $\pm$ 18cc considering that all cases received blood equal to lost volume during recovery. ICU stay all cases spend at least 12hours as a routine except few cases spend 24hours according to postoperative course. The minimum hospital stay was one day and maximum was three days. There were four cases of wound infection; two cases with dural tear that sealed with bandage, and two cases with prolonged galeal haematoma that last about twelve's days post-operative. No brain injury, no anaesthetic complications, no CSF leakage, and no mortality. 32% of studied group become on the mediumshape head (mesocephalic); the remaining cases show some improvement in comparison to their cranial index preoperative and sixths months' post-operative; but still to some extent within the deformed side. There were two cases with complete reclosure of affected suture. Also, as we operate early within the first sixth months of age there is high percentage (60%) of incomplete suture closure radiologically on 3D. Radiologically detected silver beaten appearance presented in 80% of studied group in 3D; while in ordinary plain X- ray all were negative.

**Table 1: Socio-demographic data of studied group**

	Sex		Consanguinity		Similar conditions in family	
	male	female	yes	no	yes	no
No	28	22	6	44	4	46
%	56	44	12	88	8	92

This table demonstrates that only three cases of studied group show positive consanguinity. Two cases show history of similar family condition.

**Table 2: Clinical presentation**

	No	%
Deformity alone	34	68
Deformity plus manifestation of increased ICP	10	20
Deformity plus fits	4	8
Deformity plus delayed milestones	2	4

This table demonstrates that the majority of cases of the studied group presented with deformity alone 68%. Other clinical presentations as manifestations of increased intracranial pressure, fits, and delayed milestones plus deformity was 20%, 8%, and 4% respectively. Manifestations of increased intracranial pressure were in the form of attacks of irritable crying and unexplained attacks of vomiting that push the pediatrician to refer these cases.

**Table 4: Demonstration of operative time, blood loss, and ICU stay**

	Operative time in hours	Estimated blood loss(cc)	ICU stay period in hours	Hospital stay period in days
Mean	1.30	56	14	1.8
Median	1.50	60	12	2
Std. Deviation	0.30	18	5	0.6
Minimum	1.00	30	12	1
Maximum	2.00	100	24	3

This table showing that; as regard mean operative time was one and half hour, minimum time was one hour and maximum time two hours, with stander deviation ± half an hour. Estimated blood loss the mean loss was 56cc, minimum 30cc, and maximum was 100cc, with stander deviation ±18cc considering that all cases received blood equal to lost volume during recovery. ICU stay all cases spend at least 12hours as a routine except few cases spend 24hours according to postoperative course. The minimum hospital stay was one day and maximum was three days.

**Table 5: Complications**

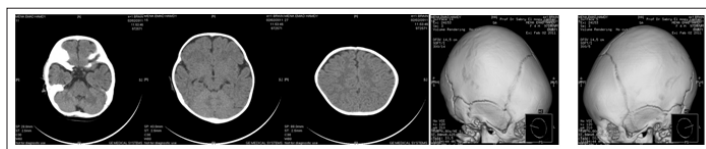
	Wound infection	Dural tear	Brain injury	CSF leakage	Prolonged galeal hematoma	Anesthetic complications	Death
No	4	2	-	-	2	-	-
%	8	4	0	0	4	0	0

(CSF: cerebrospinal fluid) This table showing that there were two cases of wound infection; single case with dural tear that sealed with bandage, and single case with prolonged galeal haematoma that last about twelve's days post-operative. No brain injury, no anaesthetic complications, no CSF leakage, and no mortality.

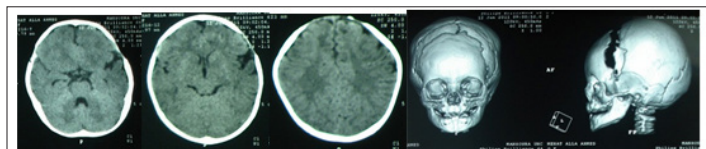
**Table 6: Changes in head shape preoperative and sixths months post-operative according to cranial index**

	Long head (schaphocephalic)		Medium head (mesocephalic)		Short head (brachycephalic)	
	Pre.	Post.	Pre.	Post.	Pre.	Post.
No	14	12	0	16	36	22
%	28	24	0	32	72	44

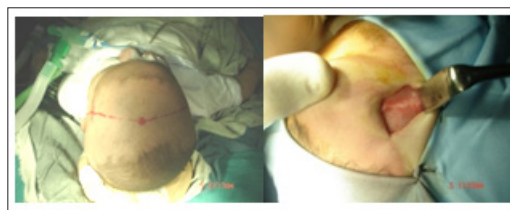P value (0.034) is significant. This table showing the degree of progress of head shape, from brachycephalic side to mesocephalic side. And the progress from schaphocephalic side to mesocephalic side. Although 32% of studied group become on the medium shape head (mesocephalic); the remaining cases show some improvement according to comparison of their CI preoperative and sixths months' post-operative; but still to some extent within the deformed side.

**Sample cases**

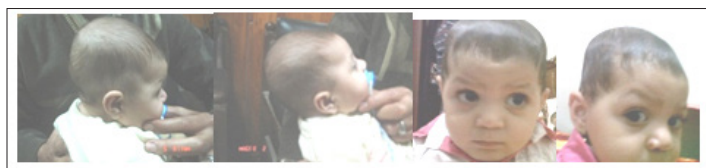**Figure 1 a:** CT brain of case one showing brachycephalic cranial deformity without brain abnormality. 3D reconstruction of the same patient showing complete closure of both coronal sutures, with preserved remnant of its serration at its upper third bilaterally; closed anterior fontanel, and skull lacunae at parieto-occipital region bilaterally.



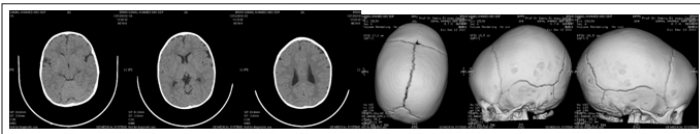
**Figure 1 b:** 6th months CT brain of the above case with improved brachycephalic deformity, and brain growth. 3D views show still opened suturectomy site, regression of deformity, and decreased skull lacunae.



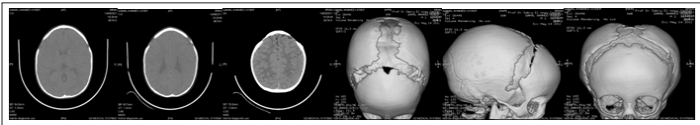
**Figure 1 c:** Intraoperative photos of the above case (left) showing surgical position, (right) show the upper part of the suture partially closed with remnant external serration.



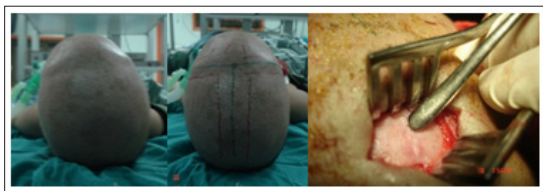
**Figure 1 d:** Lt preoperative photo with apparent deformed sloped forehead (brachycephalic). Rt 6th months post-operative photo with improved craniofacial proportion.



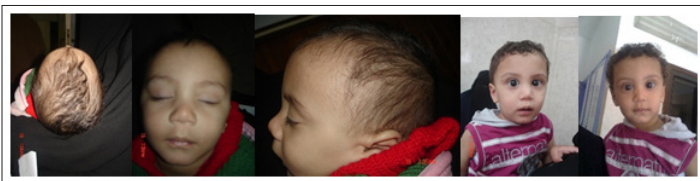**Figure 2 a:** CT brain of case two ,showing bifrontal sloping with elongation of the head.3D reconstruction views of the same case showing; complete synostosis of both coronal sutures and partially synostosed sagittal with multiple islands of complete closure, and bilaterally skull lacunae at parietooccipital regions.



**Figure 2 b:** 6th months follow up CT brain showing, improved brain growth, and improved deformity toward the mesocephalic side. 3D views show still opened suturectomy site, regression of deformity, and decreased skull lacunae.



**Figure 2 c:** intraoperative photos showing surgical positioning; apparent bridged bicoronal after shaving; and extent of wound and appearance of synostotic suture.



**Figure 2 f:** preoperative and 6th months postoperative photos of the above cases.

## Discussion

The etiology of primary craniosynostosis is unknown, and the condition almost is sporadic in families and genetic syndromes account for 10 to 20% of cases of primary craniosynostosis [2,17]. In this study, only six cases show positive consanguinity and also only four cases show history of similar condition in family. These findings denote that primary craniosynostosis is sporadically distributed in families and syndromic cases due to genetic mutations or inheritance are very rare. in spite of craniosynostosis is present at birth, it is not always diagnosed when mild. Usually it is diagnosed as a cranial deformity in the first few months of life. The diagnosis relies on physical examination and radiographic studies, including plain radiography and computed tomography (CT). Clinical history should include complications of pregnancy, duration of gestation, and birth weight [18]. Accurate diagnosis of isolated sagittal craniosynostosis can be made clinically and operative correction can proceed without the need for radiological investigations, unless the clinical features are not completely typical. In this work the selected age group was in the first sixths month, and all cases show clinical deformity in different degrees, either symmetrical as brachycephaly (bilateral coronal); scaphocephaly, and trigonocephaly or asymmetrical as anterior or posterior plagiocephaly (unilateral coronal, or unilateral

lambdoid respectively). Complete physical (especially head circumference, and cranial index) and radiological (especially 3D reconstruction of skull) evaluation, were done for all cases and both clinical, and radiological evaluation were compatible. The message is that the craniosynostosis is mainly clinical diagnosis although all cases should be fully investigated preoperatively. However, in this study we observed that early youngest cases show clinical deformity before it is completely evident on the radiological studies and this may be explained by; in early course of the disease the stenosis started partially then completed with the progress of age. On the other hand, the manifestations of increased intracranial pressure were observed in number of cases of the studied group. These manifestations were in the form of attacks of irritable crying and unexplained attacks of vomiting with failed ordinary management by pediatrician. These manifestations were found in 20% of cases of this work (with single or multiple sutures collectively). This is coincident to the main stream of literature where the chance of increased intracranial pressure with one suture craniosynostosis is 7%. With cases of multiple suture craniosynostosis the incidence of increased intracranial pressure can be as high as 62% [5,19]. The pattern of deformity distribution among male and female cases in this study revealed that the brachycephalic (bilateral coronal) and anterior plagiocephalic (unilateral coronal) deformities were common in female gender (45.5% and 36.4% respectively). Schaphocephalic deformity (sagittal craniosynostosis) was common in male gender (50%). these finding was almost coincident to the main stream results of literatures. concluded that sagittal craniosynostosis, is more frequent in males, (70%- 90% of cases). On the other hand, coronal craniosynostosis has a slightly higher incidence among females, (55%- 70%). Bilateral involvement of the coronal suture showed much female predilection, with 76% of bicoronal craniosynostosis occurring in females, as compared with the more modest 54% female majority in unicoronal craniosynostosis [20]. In this study, the most isolated suture craniosynostosis was the sagittal suture (28%), followed by coronal suture (16%) and less frequently isolated sutures were metopic followed by lambdoid; and two cases non-syndromic pan synostosis (4%). isolated sagittal synostosis, the most common form, accounts for 57% of isolated synostosis cases, with isolated coronal synostosis accounting for 18–24%, isolated metopic synostosis between 4 and 10%, and isolated lambdoid synostosis being the least common, making up only 1–4% of the cases [21,22].

In this study, we utilize the minimally invasive early endoscopic assisted suturectomy (first six months of age), mean operative time was one and half hour, (1 - 2hrs), with stander deviation half an hour. Estimated blood loss the mean loss was 56cc, (30 - 100cc) with, stander deviation 18cc. All cases received blood equal to lost volume during recovery. All cases spend at least 12hours in ICU as a routine except 6 cases spend 24hours due to chest wheeze. The minimum hospital stay was one day and maximum was three days. When comparing these results with the results of cranial vault reconstruction surgery of similar group, it is clear that this minimally invasive approach is much better. However, we cannot exclude the role of reconstructive surgery in older children, or in residual deformity of younger one. This aforementioned comparison is in accordance to Jimenez and Barone work, where they concluded that results with an endoscopic approach to the treatment of craniosynostosis is much better; and demonstrated that the best results are obtained when patients are referred very early in life [1,13,23,24]. as regard complications of this minimally invasive approach among all cases (50cases); there were 2 cases

with dural tear, and 2 cases with prolonged galeal hematoma. No brain injury, no anesthetic complications, no CSF leakage, and no mortality. When comparing these results with that of reconstructive procedures; one found that it is much simpler and extremely safe approach. These findings are coincident to Esparza, et al. where they review the results and complications of different surgical approaches, and found that; the most frequent complication was postoperative hyperthermia of undetermined origin (13.43% of the cases), followed by infection (7.5%), subcutaneous hematoma (5.3%), dural tears (5%), and CSF leakage (2.5%). The total mortality rate of the series was 2 out of 283 cases (0.7%) [14]. They concluded that endoscopic assisted osteotomies presented the lowest complication rate [14]. In this study head circumference and cranial index was recorded preoperatively and in each visit postoperatively by measuring tape. Radiological cranial index on axial CT was recorded pre-and on 6th month postoperatively and the results show progression of head circumference (as it estimated by highly significant P value  $< 0.001$ ) and this is an indicator of brain growth [22]. As regard, cranial index both clinical and radiological evidences show marked improvement (as estimated by highly significant P value  $< 0.05$  and  $< 0.006$ ) and this improvement reflected on the head shape where we get a group of cases with medium shape head (mesocephalic 32%) postoperatively. The remaining cases show some improvement according to comparison of their CI preoperative and six months' postoperatively; but still to some extent within the deformed side. This may have attributed to that we don't do immediate reconstructive corrective surgery; but depend on brain growth and early interference based on the hypothesis that the content induces the container. When comparing these results with the Jimenez and Barone review of their series of endoscopic assisted suturectomy. Head circumference measurements were closely followed to ensure that normal and proper brain growth took place without restriction. Follow up of head circumference was evident that there were no cases in which head or brain growth was restricted. Furthermore, analysis also indicated that proportional growth occurred. The mean preoperative cephalic index was 98 (range 82–111). Late postoperative cephalic index ( $\geq 1$  year) was 83 (range 79–92). Overall, there was a 15% decrease from preoperative baseline [13]. We get a low incidence of complications, blood transfusion, and operative time and hospital stay that is in accordance with Jimenez and Barone work. Also, progression of head growth and regression of evident deformity was clear in this study as it revealed by a highly significant P value ( $< 0.001$ ) of head circumference, and highly significant P value ( $< 0.05$  and  $< 0.006$ ) of radiological and clinical cranial index that reflected on changes on head shape. We get a new group of mesocephalic head (32%) and regression of the deformity on the other patients with different degrees. after surgery for isolated sagittal craniosynostosis in children, there is a very low incidence of reformation of the sagittal suture. The variability in reformation of the suture suggests its heterogeneous etiology and pathogenesis. Genetic predisposition to synostosis, inclusion of undiagnosed syndromic patients and current operative techniques may be some of the factors responsible for the low incidence of reformation after surgery for "isolated" sagittal synostosis [25]. A series of 114 patients with long term follow up between 1987 and 2000. Seven children were found to have reformation of at least a part of the sagittal suture; thirty-five had reossification of the craniectomized bone defects without any part of the sagittal suture being visible on the radiographs and forty-two children had no bone replaced over the sagittal sinus [25]. In this study, we have 2 cases of complete recluser of sagittal suture; six months postoperatively and the remaining 48

cases show different degree of reossification; or no bone at all at the suture site. Skull lacunae were observed in the majority of cases (80%) of this work, especially with involvement of more than one synostosed suture. These skull lacunae or silver beaten appearance were observed with different degree in 3D reconstruction images especially in the parietooccipital region. In conventional plain x-rays these signs are not detected. Although these lacunae are not felt clinically on palpation, it is well visualized in 3D reconstruction evaluation. The presence of this silver beaten is explained as radiological manifestation of increased intracranial pressure. This feature secondary to pulsatile pressures toward the internal tabular of cranium secondary to increase intracranial pressure in the form of lacunar skull [11].

## Conclusion

Craniosynostosis is the premature closure of calvarial sutures. The evaluation of infants suspecting to have craniosynostosis should include complete clinical evaluation and should be radiologically investigated with conventional plain radiograph, CT scan, 3D reconstruction and may be MRI [26,27]. Timing of surgery is an active topic of discussion among craniofacial surgeons and neurosurgeons; and many surgical approaches were developed for the management of craniosynostosis; ranging from simple craniectomy to global cranial vault reconstruction. Endoscopic assisted suturectomy is minimally invasive approach with a very narrow range of complications, very limited need to blood transfusion and if it occurs, it is small volume in relation to total volume. Very short ICU and hospital stay also decrease the economic load. However, this approach cannot be the only alternative in surgical management of craniosynostosis especially complex syndromic cases or residual deformity after simple suturectomy [28-30].

## References

1. Barone CM, Jimenez DF (1998) Endoscopic craniectomy for early correction of craniosynostosis. *Plast Reconstr Surg J* 104: 1965-1973.
2. Behrman RE, Kuelman R, Jenson H (2000) Craniosynostosis, in Kliegman R (ed): *Nelson Textbook of Pediatrics*, ed 16. Philadelphia: WB Saunders 1831-1832.
3. Aleck K (2004) Craniosynostosis syndromes in the genomic era. *Semin Pediatr Neurol J* 11: 256-261.
4. Stephen M, Warren and Michael T, Longaker, (2001) The Pathogenesis of Craniosynostosis in the fetus. *Yonsei Medical Journal* 42: 646-659.
5. Panchal J, Utchin V (2003) Management of craniosynostosis. *Plast Reconstr Surg* 111: 2032-2048.
6. Goodrich JT (1991) Craniofacial reconstruction for craniosynostosis, *Plastic Techniques in Neurosurgery*. New York: Thieme 75-108.
7. Baker SB, Weinzwieg J, Kirschner RE, Bartlett SP (2002) Applications of a new carbonated calcium phosphate bone cement: Early experience in pediatric and adult craniofacial reconstruction. *Plast Reconstr Surg J* 109: 1789.
8. Alvarez-Garijo JA, Cavadas PC, Vila MM, Alvarez-Llanas A (2004) Sagittal synostosis: results of surgical treatment in 210 patients. *Childs Nerv Syst J* 17: 64-68.
9. Boulos PT, Lin KY, Jane JA Jr, Jane JA Sr (2004) Correction of sagittal synostosis using a modified Pi method. *Clin Plast Surg J* 31: 489-498.
10. Singer S, Bower C, Southall P, Goldblatt J (1999) Craniosynostosis in Western Australia, 1980- 1994: a population-based study. *Am*

- J Med Genet 83: 382-387.
11. Mehmet Davutoglu, Nazan Okur, Hamza Karabiber, Ekrem Guler, Mesut Garipardic, et al. (2010) Craniosynostosis associated with lacunar skull. Euro J Gen Med 7: 104-106.
  12. Gregory JA Murad, Mark Clayman, Sno White, Leigh Ann Perkins, David W Pincus (2005) Endoscopic-assisted repair of craniosynostosis. Neurosurg Focus 19: E6.
  13. Jimenez DF, Barone CM (2010) Multiple-suture nonsyndromic craniosynostosis: early and effective management using endoscopic techniques. Clinical article. J Neurosurg Pediatr 5: 223-231.
  14. Esparza J, Hinojosa J, García-Recuero I, Romance A, Pascual B, et al. (2008) Surgical treatment of isolated and syndromic craniosynostosis. Results and complications in 283 consecutive cases. Neurocirugía J 19: 509-529.
  15. Christophis P, Junger TH, Howaldt HP (2001) Surgical correction of scaphocephaly: experiences with a new procedure and follow up investigations. J Maxillofac Surg 29: 33-38.
  16. Cohen MM, MacLean RE (2000) Craniosynostosis. Diagnosis, Evaluation and Management. New York: Oxford University Press.
  17. Hidar Kabbani, Talkad S (2004) Craniosynostosis. J American Family Physician 69: 12.
  18. Mooney MP, Siegel MI (2003) Understanding craniofacial anomalies. BJS 90: 124-137.
  19. Sloan GM, Wells KC, Raffel C, McComb J (1997) G: Surgical treatment of craniosynostosis: outcome analysis of 250 consecutive patients. Pediatrics 100: E2.
  20. Ruiz-Correa, Raymond W Sze, Jacqueline R Starr, Hen-Tzu J Lin (2006) New Scaphocephaly Severity Indices of Sagittal Craniosynostosis: A Comparative Study with Cranial Index Quantifications; Cleft Palate–Craniofacial Journal 43.
  21. Cohen MM (2000) Craniofacial disorders caused by mutations in homeobox genes MSX1 and MSX2. J Craniofac Genet Dev Biol 20: 19-25.
  22. Renier D, Lajeunie E, Arnaud E, Marchac D (2000) Management of craniosynostosis. Childs Nerv Syst 16: 645-658.
  23. Jimenez CM, Barone DF (2002) Role of endoscopy in craniofacial surgery. Craniofacial surgery: science and surgical technique. Philadelphia: WB Saunders 173-187.
  24. Jimenez DF, Barone CM, Cartwright CC, Baker L (2002) Early management of craniosynostosis using endoscopic-assisted strip craniectomies and cranial orthotic molding therapy. Pediatrics J 110: 97-104.
  25. Agrawal D, Steinbok P, Cochrane DD (2006) Reformation of the sagittal suture following surgery for isolated sagittal craniosynostosis. J Child's Nerv Syst 22: 375-378.
  26. Aviv RI, Rodger E, Hall CM (2002) Craniosynostosis. Clin Radiol J 57: 93-102.
  27. Gault DT, Renier D, Marchac D, Jones B (2005) Intracranial pressure and intracranial volume in children with craniosynostosis. Plast Reconstr Surg J 90: 377.
  28. Mehta VA, Bettgowda C, George IJ, Edward SA (2010) The evolution of surgical management for craniosynostosis. Neurosurg Focus 29: E5.
  29. Tamburrini G, Caldarelli M ML, Santini P, Di Rocco C (2005) Intracranial pressure monitoring in children with single suture and complex craniosynostosis: a review. Childs Nerv Syst 21: 913-921.
  30. Thomas GP, Wilkie AO, Richards PG (2005) FGFR3 P250R mutation increases the risk of reoperation in apparent 'nonsyndromic' coronal craniosynostosis. J Craniofac Surg 16: 347-354.

**Copyright:** ©2018 Ramadan Shamseldien, et al. This is an open-access article distributed under the terms of the Creative Commons Attribution License, which permits unrestricted use, distribution, and reproduction in any medium, provided the original author and source are credited.