

Complications of decompressive lumbar spine procedures without instrumentations – an institutional experience

Ramadan Shamseldein, Mohamed Mousa, Ayman Wageh, Ihap Bedier
Neurosurgery Department, Shebin Elkom Teaching Hospital, Shebin Elkom, Egypt

Abstract

Background

Till now, there is insufficient documentation of operative complications in spine surgery, and the expected results are far less predictable if the actual indication for surgical intervention is not clear. Complication could be defined as ‘a condition that directly or indirectly results from surgical intervention and disrupts the planned outcome of the surgery.’ So, spine surgeons should be aware of these events and know how to deal with them.

Aim

To detect the number and percentage of moderate and/or major operation-related complications associated with the relatively repeated and popularized neurosurgical procedures performed at the Neurosurgical Department, Shebin Elkom Teaching Hospital, to analyze our work in relation to published literature that addresses this topic, so as to optimize the future practice.

Patients and methods

A retrospective study was conducted on documented operation-related complications of patients operated upon at the Neurosurgical Department, Shebin Elkom Teaching Hospital, between March 2011 and March 2019. This study involved patients who underwent decompressive lumbar spine procedures without instrumentation. The operations were performed by neurosurgeons with the same professional degree but with different number of operated cases. Any decompressive surgery with instrumentation techniques was excluded.

Results

A total number of 3496 patients were operated upon between March 2011 and March 2019, of whom 1087 fulfilled the inclusion criteria. Their medical records were reviewed for documentation of the existed complications related to surgery. The number of documented moderate and/or major operation-related complications was 124 (11.41%) cases from the total number of the studied group.

Conclusion

Till now, there is insufficient inclusive documentation of operative complications in spine surgery. In this study, the number and percentage of moderate and/or major complications related to different decompressive lumbar surgery techniques without instrumentations could be detected, and it was found that most of the identified complications lie within the reported incidence. With insightful understanding of these complications, surgeons could adequately analyze and evaluate risk factors in patients and procedure-related factors and then develop preventive measurements to reduce the rate of these complications.

Keywords: Discectomy, fenestration, laminectomy, lumbar spine, operative complication

INTRODUCTION

Any indication for surgical spine procedure has to be documented as the expected results are far less predictable if the actual indication for surgical intervention is not clear. Therefore, interest must be shown to any complications related to these interventions [1]. Till now, there is insufficient

Correspondence to: Ramadan Shamseldien, MD,
Department of Neurosurgery, Shebin Elkom Teaching Hospital,
Shebin Elkom 11697, Egypt
Tel: +20 100 125 1003;
E-mail: ramadangelal77@gmail.com

This is an open access journal, and articles are distributed under the terms of the Creative Commons Attribution-NonCommercial-ShareAlike 4.0 License, which allows others to remix, tweak, and build upon the work non-commercially, as long as appropriate credit is given and the new creations are licensed under the identical terms.

Submitted: 28-May-2020 Revised: 28-Jun-2020 Accepted: 17-Jun-2020 Published: 23-Dec-2020

How to cite this article: Shamseldein R, Mousa M, Wageh A, Bedier I. Complications of decompressive lumbar spine procedures without instrumentations – an institutional experience. J Med Sci Res 2020;3:309-14.

Access this article online

Quick Response Code:



Website:
www.jmsr.eg.net

DOI:
10.4103/JMISR.JMISR_34_20

inclusive documentation of operative complications in spine surgery. Some authors studied the spine surgery-related complications by analysis of previously published articles with certain specific criteria, and they concluded that among 79 471 patients, 16.4% were complicated cases, and the incidence was high in thoracolumbar surgery (17.8%) and then cervical spine surgery (8.9%) [2].

Complication could be defined as 'a condition that directly or indirectly results from surgical intervention and disrupts the planned outcome of the surgery, and can be further graded as minor, moderate, or major.' Minor complications need 1 day or no increase in the hospital stay with minimal or no additional treatment required. Moderate complications need treatment and increase the hospital stay up to 1 week. Major complications need specific treatment, increase the hospital stay by more than 1 week, and/or create long-term sequelae (≥ 6 months) [3]. A meta-analysis of 42 published articles suitable for certain inclusion criteria from 9504 articles between 1990 and 2014 to study the complications of different techniques for lumbar disc surgery was done.

Durotomy was seen in 3.9 and 4.5% in open and endoscopic techniques, respectively; postoperative cerebrospinal fluid (CSF) leakage was seen in 1.3% for open and 0.6% for endoscopic techniques, respectively; and wound hematoma was seen in 0.5, 1.2, and 0.6 in open, endoscopic, and microdiscectomy, respectively. Wound complications were reported in 2.1, 1.2, and 0.5% in open, endoscopic, and microdiscectomy techniques, respectively [4]. Another prospective study was done on 1772 patients operated upon for lumbar disc surgery; it studied the risk factors of surgical site infection and found that surgical site infection was 2.3%, deep wound infection was 0.22%, superficial wound infection was 1.7%, durotomy was 1.2%, nerve root injury was 1.1%, and wound hematoma was seen in 1.3% [5]. In same context, another work on 99 152 patients studied the risk factors for wound complications following spine surgery and reported 2.2% incidence of wound infection, distributed as follows: 0.8 deep, 0.9 superficial, 0.3 dehiscence, and 0.4 dead space infection [6]. Durotomy is a terrible complication in spine surgery that could occur even with expertise. The current reported incidence of durotomy and eventually CSF leaks varies between 1.6 and 17.4% [7,8]. In a cohort series of 500 patients who underwent first-time lumbar laminectomy, single level up to three levels, durotomy rate was 10.00%. A retrospective review of 4835 lumbar spine operations over a 10-year period reported an incidental durotomy of 11.3% [9]. Similarly, another series found an incidence of 1.2%, and in patients with recurrent disc disease, the incidence was 7.14% [8].

Instability and iatrogenic spondylolisthesis as a complication of postlumbar decompressive surgery was studied in one research work reviewing 241 published articles; only 24 articles fulfilled the inclusion criteria and included 2553 patients. The work found that the inclusive incidence of newly developed or

increased degree of spondylolisthesis at the mean postoperative follow period was 5.5%, whereas reoperated cases owing to instability postoperatively were 1.8%. Patients with pre-existed spondylolisthesis were 10 times more liable to progression postoperatively and so were reoperated than patient with only lumbar canal stenosis without preoperative listhesis [10].

Regarding wrong site surgery, the spine surgery was involved in 5–8% of all wrong site surgery. In another report among 76 wrong site surgery reported by 61 orthospine surgeon, 31 (43.6%) cases were spine surgery. The majority of missed level operation was performed in lumbar spine followed by cervical spine and thoracic spine [11–14].

Abdominal complications of lumbar disc surgery occur in 0.016–0.06% of cases, with retroperitoneal major vessel injury having the higher incidence followed by visceral injuries. Isolated intestinal injury is a very rare complication of prolapsed lumbar disk surgery, and their literature search revealed only 18 cases [15]. Regarding retroperitoneal major vessel injury (postlumbar discectomy), the first reported case in United Kingdom was in 1991 owing to abdominal aortic tear; the documented mortality rates are very high (78%) with injury to abdominal aorta and the rate increase to 89% with inferior vena cava injury and decrease to some extent with iliac vessels injury [16]. In one series of lumbar disc surgery of 2590 patients, only one case of retroperitoneal vessel injury was reported, and according to the review of that series, this seldom hazardous complication can occur in 0.01–0.05% of cases. Certain risk factors that may increase the chance for this bad event to occur are previous lumbar or abdominal surgery, occurrence of peridiscal fibrosis, deep intrusion of pituitary rongeur, bad positioning of the patients, and associated anomalies [17]. In the same context, a report of three cases of iatrogenic main vascular injury was published: the first case involved left common iliac artery and bilateral common iliac veins, and the patient died after trial of reanastomosis surgery, the second case involved left common iliac artery and vein injuries, where definitive management occurred, and the patient was discharged without any complications, and the third case involved left common iliac artery injury and was repaired without any consequences (cited incidence of 0.01–0.1%, with life-threatening complications) [18].

Pneumocephalus as a complication of lumbar surgery is very rare. Only eight cases have been described in the literature, and of them, six cases were complications from intraoperative dural tear. Symptomatic compressive pneumocephalus is an exceptional complication following lumbar surgery. A conservative treatment might be adequate even in the presence of severe symptomatic manifestations [19].

Aim

The aim was to detect the variety, number, and percentage of moderate and/or major operation-related complications associated with the repeated and popularized neurosurgical procedures conducted at the Neurosurgical

Department, Shebin Elkom Teaching Hospital, to analyze our work in relation to the published literature that addresses this topic to optimize future practice.

PATIENTS AND METHODS

This is a retrospective study for documentation of operation-related complications among patients operated upon at the Neurosurgical Department, Shebin Elkom Teaching Hospital, between March 2011 to March 2019 for decompressive lumbar spine procedures without instrumentation. The study included all neural decompressive surgical lumbar procedures (microdiscectomy, interlaminar approach, unilateral fenestration, and laminectomy), either first-time surgery or recurrent surgery without instrumentations. The operations were performed by neurosurgeons with the same professional degree but with different number of operated cases. Exclusion criteria involved any decompressive surgery with instrumentation techniques. According to the data from medical record department of our hospital, a total number of 3496 patients were operated on, of whom 1087 cases fulfilled the inclusion criteria. Their medical records were reviewed for documentation of the existed complication related to surgery globally.

RESULTS

According to medical records, 1087 cases fulfilled the inclusion criteria [608 (56%) males and 479 (44%), females]. The mean age of the patients was 43.38 years. The number of documented moderate and/or major operation-related complications was 124 cases (11.41% from total number of the studied group). These cases were classified into the following two groups: the first group of complications occurred immediately intraoperatively and/or within the first 2 days postoperatively and prolonged the hospitalization of the patients and/or needed special interference or led to special sequelae, and the second group of operation-related complications occurred during the follow-up period (within the first 6 months from surgery) and/or need special interference or led to special sequelae (Fig. 1 and Tables 1–3).

SAMPLE CASES

Case 1

A 50-year-old male patient with long-standing history of low back pain (LBP) developed bilateral sciatica more on right side not responding to medical treatment and physiotherapy. MRI lumbo-sacral spine (LSS) showed marked discogenic stenosis at L4–L5 level. Right-sided endoscopic discectomy: unintended durotomy occurred, and the patient developed postoperative CSF leakage and was managed conservatively; the wound stopped leaking after 3 weeks. Two MRI scans was done first 3 weeks postoperatively, where the wound was still leaking, and the second was done 2 months postoperatively after wound was completely clean and dry and stopped leaking (Fig. 2a–c).

Case 2

A 50-year-old male patient with a history of previous laminectomy (L4 partial and L5 complete) many years ago

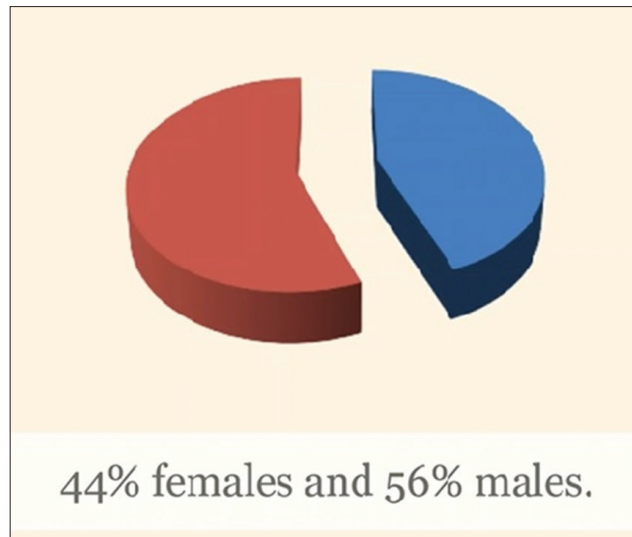


Figure 1: Sociodemographic data: sex distribution: male (56%) and female (44%).

Table 1: Age distribution of the patients	
Number of patients	1087
Mean age	43.38
Minimum	24
Maximum	68

Table 2: First group	
Surgical complication	n (%)
Dural tear	30 (2.7)
Direct thecal contusion or lacerations	2 (0.18)
Root injury of any degree	11 (1.012)
Postoperative hematoma that need urgent evacuation	11 (1.012)
Deep wound infection	32 (2.94)
Meningitis	6 (0.55)
Pneumocephalus	2 (0.18)
Bowel or visceral injury	1 (0.092)
Main vascular injury	1 (0.092)

Table 3: Second group	
Surgical complication	n (%)
Missed level	13 (1.2)
Foreign body	6 (0.55)
Iatrogenic listhesis	9 (0.82)

presented with LBP and neurogenic claudication. Lumbosacral MRI showed adjacent level disease above. One month after decompressive surgery, the patient developed progressive severe LBP with limitation of lower extremity movement and urinary urgency, so MRI was done and showed deep wound infection and epidural collection (Fig. 3a and b).

Case 3

A 46-year-old male patient, a known case of diabetic on insulin,

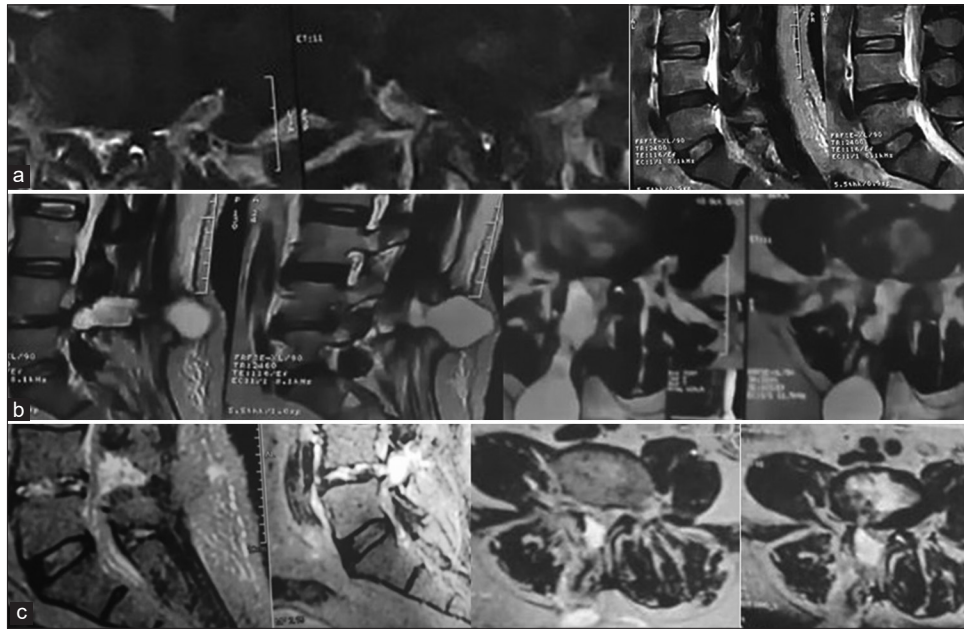


Figure 2: (a) Preoperative MRI. (b) MRI at 3 weeks postoperatively show the track and subcutaneous pseudomeningocele. (c) MRI 2 months postoperatively, the condition shows a regressive course.

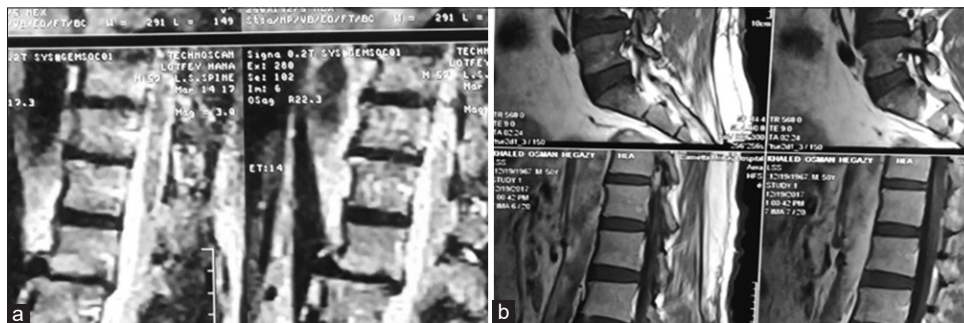

Figure 3: (a) MRI at presentation with old L5 laminectomy and L4 partial laminectomy and above levels stenosis. (b) MRI follow-up after deterioration shows deep wound infection and epidural collection.

6 years ago was operated by left L5–S1 microdiscectomy. He came back with left sciatica and left partial foot drop. MRI lumbosacral showed recurrence at the same level with cranial migration of the disc. The same previous left L5–S1 microdiscectomy technique was repeated. In the postoperative course, the sciatica improved, but the patient started progressive severe LBP not responding to medical treatment. After 4 months, follow-up MRI was done and showed discitis at the operated level (Fig. 4 and b).

DISCUSSION

Disc disease of lumbar spine and its associated conditions of lower back pain and neurological problems are one of the most common groups of health disorders affecting adults and have considerable economic implications. Different surgical techniques for neural decompression without instrumentations have been evolved such as laminectomy, interlaminar approach, unilateral fenestration, microdiscectomy, and endoscopic discectomy. These procedures utilized for

decompressive lumbar surgery are popular and constitute a large percentage of daily neurosurgical spine practice, although there is insufficient inclusive documentation of operative complications related to spine surgery. In this work, the total number of studied cases were 1087 patients, of whom the total number of surgically complicated cases were 124 (11.4%) cases. This finding is in accordance with the stream of literature review, such as the analytical study of Nasser *et al.* [2], where they found in their work that the percentage of complications related to surgical procedures is high in thoracolumbar spine surgeries, up to 17.8%. The studied group was classified into two major groups of complications: the first group of complications occurred immediately intraoperatively and/or within the first 2 days postoperatively and prolonged the hospitalization of the patients and/or needed special interference or led to special sequelae, and the second group occurred during the follow-up period, within the first 6 months from surgery, and/or needed special interference or led to special sequelae. These two groups met the moderate and major grading of Rampersaud

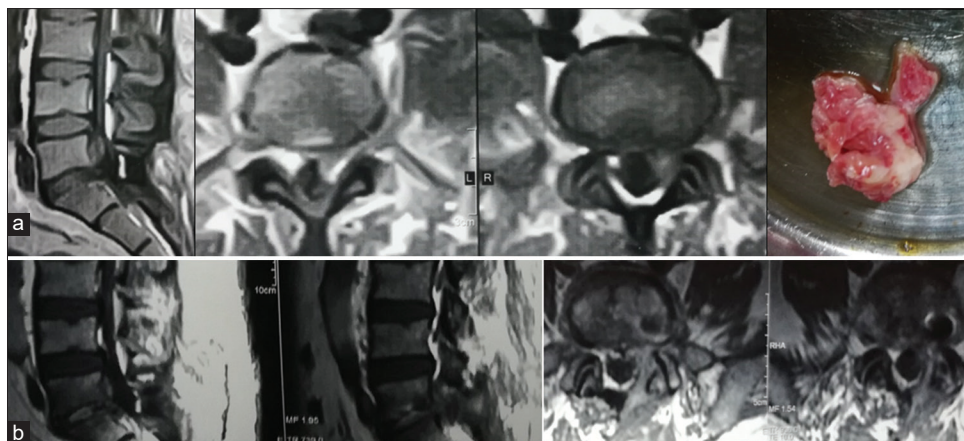


Figure 4: (a) Preoperative MRI shows the cranially migrated prolapsed recurrent disc and operative photograph of that disc that extracted as one mass. (b) 4 months postoperative follow-up with evident discitis.

et al. [3]. The minor group of Rampersaud *et al.* [3] grading is not considered in this work as it does not affect hospitalization and does not lead to special sequelae or interference.

Multiple studies reported varied incidences of durotomy during lumbar surgery with different techniques. The current literature studies reported incidence that varies between 1.6 and 17.4%. Adam and colleagues reported an incidence of 3.6%, Shriver and colleagues reported an incidence between 3.9 and 4.5%, Habiba and colleagues observed an incidence of durotomy of 1.2%, Bydon and colleagues reported an incidence of 10%, and Albayrak and colleagues reported an incidence of 1.2%. When patients with recurrent disc disease were excluded from the study, the incidence decreased to 0.82%. In patients with recurrent disc disease, the incidence was 7.14% [4,5,7–9]. In the studied group, dural tear was observed in 30 (2.7%) patients, which is located towards the lower limit of the incidence reported by previous studies.

The reported incidence of wound hematoma ranged between 0.5 and 1.2% [4,5]. This complication was found in the presented study in 1.012%, which is in agreement with the reported incidence in the current literature studies.

Regarding neural injury found in this study, nerve root injury was seen in 1.012% and thecal contusion in 0.18%. This is in agreement with the reported incidence of neural injury of 1.1% in lumbar disk surgery [5].

Piper *et al.* [6] reported an overall incidence of wound infection in 2.2%, of which, 0.8% represented deep wound infection. Habiba. *et al.* [5] found that the overall incidence of surgical site infection was 2.3%, and deep wound infection was 0.22%. Lastly, Shriver *et al.* [4] reported an incidence between 0.5 and 2.1% of wound complications in different techniques for lumbar disk surgery. The results of the presented study in this regard reported 2.94% (32 cases) deep wound infection cases and 0.88% (two cases) complicated with meningitis, and these incidences were slightly higher than the reported incidence by the aforementioned studies.

According to the finding of Guha *et al.* [10], the overall incidence of newly developed iatrogenic or increased degree

of spondylolisthesis at the mean postoperative follow period was 5.5%, whereas reoperated cases owing to instability postoperatively was 1.8%. The findings in the present study in this regard during the first 6 months postoperatively showed nine (0.82%) cases of iatrogenic spondylolisthesis had occurred, and this value was significantly less than the values of the former review.

In this work, 13 (1.2%) cases of surgery on missed level were picked up at the follow-up period. This finding is in accordance with a stream of reports in the literature, where the reported rate of wrong site surgery ranged from 0.09 to 4.5 per 10 000 surgeries, and the spine surgery was involved in 5–8% of all wrong site surgery [11,12]. In another report, 43.6% of wrong level cases were related to the spine surgery, and the majority of missed level operation was performed in lumbar spine followed by cervical spine and thoracic spine [13,14].

Regarding the abdominal complications during lumbar disc surgery, Kilbas *et al.* [15] reported a rate of 0.016–0.06% of cases, with retroperitoneal vascular injuries constituting the majority of these complications. Keskin *et al.* [18] cited an incidence of 0.01–0.1%, with life-threatening complications in case of iatrogenic main vascular injury. Papadoulas *et al.* [17] recorded rare life-threatening complication in one to five cases every 10 000 (0.01–0.05%). This means that the overall reported incidence ranged from 0.016 to 0.1%. In this work, one case of abdominal vascular injury and one case of retroperitoneal vascular injury were documented among the studied group (0.092% for each), and this finding lies within the reported incidence of the previous reviews.

The occurrence of pneumocephalus as a complication of lumbar surgery is very rare, and conservative treatment might be adequate even in the presence of severe symptomatic manifestations. A total of eight cases have been described in the literature. Six of them are associated with intraoperative dural tears [19]. In this work, we picked up two cases complicating the dural tear and were managed conservatively. This number is considered high in relation to the documented cases in the literature.

CONCLUSION

Till now, there is no sufficient inclusive documentation of operative complications in spine surgery, and the expected results are far less predictable if the actual indication for surgical intervention is not clear. As most are preventable and treatable, more attention should be paid for complications related to these procedures. In this study, the number and percentage of moderate and/or major complications related to different decompressive lumbar surgery techniques without instrumentations could be detected, and it was found that most of identified complications lie within the reported incidence published in this field, with the exception of a single complication (postoperative pneumocephalus complicating dural tear), which was managed conservatively. With insightful understanding of these complications, surgeons could adequately analyze and evaluate risk factors in patients and procedure-related factors and then develop preventive measurements to reduce the rate of these complications. Further prospective multi-institutional cohort study is advisable so as to detect and optimize relevant surgical practice.

Declaration of patient consent

The authors certify that they have obtained all appropriate patient consent forms. In the form the patient(s) has/have given his/her/their consent for his/her/their images and other clinical information to be reported in the journal. The patients understand that their names and initials will not be published and due efforts will be made to conceal their identity, but anonymity cannot be guaranteed.

Financial support and sponsorship

Nil.

Conflicts of interest

There are no conflicts of interest.

REFERENCES

- Banna SE, Catano A. Complications of spine surgery and litigations – managing mal practice risk. *J Clin Exp Orthop* 2015; 1:1.
- Nasser R, Yadla S, Maltenfort MG, Harrop JS, Anderson DG, *et al.* Complications in spine surgery. *J Neurosurg Spine* 2010; 13:144–157.
- Rampersaud YR, Moro ER, Neary MA, White K, Lewis SJ, Massicotte EM, *et al.* Intraoperative adverse events and related postoperative complications in spine surgery: implications for enhancing patient safety founded on evidence-based protocols. *Spine* 2006; 31:1503–1510.
- Shriver MF, *et al.* Lumbar microdiscectomy complication rates: a systematic review and meta-analysis. *Neurosurg Focus* 2015; 39:E6.
- Habiba S, Nygaard ØP, Brox JI, *et al.* Risk factors for surgical site infections among 1,772 patients operated on for lumbar disc herniation: a multicenter observational registry-based study. *Acta Neurochir (Wien)* 2017; 159:1113–1118.
- Piper KF, Tomlinson SB, Santangelo G, Van Galen J, DeAndrea-Lazarus I, Towner J, *et al.* Risk factors for wound complications following spine surgery. *Surg Neurol Int* 2017; 8:269.
- Adam D, Papacoccea T, Iliescu R, Hornea I, Moisescu C. Incidental durotomy in lumbar spine surgery incidence, risk factors and management. *Rom Neurosurg* 2015; 2015:22.
- Albayrak S, Ozturk S, Ayden O, Ucler N. Dural tear: a feared complication of lumbar discectomy. *Turk Neurosurg* 2016; 26:918–921.
- Bydon M, Macki M, Abt NB, Sciubba DM, Wolinsky JP, Witham TF, *et al.* Clinical and surgical outcomes after lumbar laminectomy: an analysis of 500 patients. *Surg Neurol Int* 2015; 6:S190–S193.
- Guha D, Heary RF, Shamji MF. Iatrogenic spondylolithesis following laminectomy for degenerative lumbar stenosis: systematic review and current concepts. *Neurosurg Focus* 2015; 39:E9.
- Devine J, Chutkan N, Norvell DC, Dettori JR. avoiding wrong site surgery: a systematic review. *Spine (Phila Pa 1976)* 2010; 35:s28–s36.
- Wong DA, Watters WC. 3rd to error is human: quality and safety issues in spine care. *Spine (Phila Pa 1976)* 2007; 32:s2–s8.
- James MA, Seiler JG, Harrast JJ, Emery SE, Hurwitz S. The occurrence of wrong site surgery self-reported by candidates for certification by the American Board of Orthopedic surgery. *J Bone Joint Surg Am* 2012; 94:e2.
- Mody MG, Nourbakhsh A, Stahl DL, Gibbs M, Alfawarah M, Garges KJ. The prevalence of wrong level surgery among spine surgeons. *Spine (Phila Pa 1976)* 2008; 33:194–198.
- Kilbas Z, Yagci G, Hakki Ozerhan I, Peker Y, Cetiner S. Small bowel transection as a rare complication of lumbar disc surgery: report of a case. *Arch Clin Exp Surg* 2015; 4:222–225.
- Ewah B, Calder I. Intraoperative death during lumbar discectomy. *Br J Anesth* 1991; 66:721–723.
- Papadoulas S, *et al.* Vascular injury complicating lumbar disc surgery. A systematic review. *Eur J Vasc Endovasc Surg* 2002; 24:189–195.
- Keskin M, *et al.* Iatrogenic major vascular injury during lumbar discectomy. *Turk Neurosurg* 2013; 23:385–388.
- Gauthé R, Latrobe C, Damade C, Foulongne E, Roussignol X, Ould-Slimane M. Symptomatic compressive pneumocephalus following lumbar decompression surgery a case report. *Orthop Traumatol Surg Res* 2016; 102:251–253.