

## Grading System for Cranial Suture Closure in Early Craniosynostosis

Ramadan Shamseldien<sup>1</sup>, Abdelhafiz Shehabeldien<sup>2</sup> and Hedaya Hendam<sup>3</sup>

<sup>1</sup>Lecturer of Neurosurgery, Shebin Elkom Teaching Hospital, Egypt.

<sup>2</sup>Professor Neurosurgery, Head Neurosurgical Department, Elsahl Teaching Hospital, Egypt.

<sup>3</sup>Assistant professor, Neurosurgery, Alazhar Faculty of Medicine, Egypt.

### \*Correspondance:

Ramadan Shamseldien, Lecturer of Neurosurgery, Shebin Elkom Teaching Hospital, Egypt, E-mail: ramadangelal77@gmail.com.

**Received:** 10 August 2017; **Accepted:** 27 August 2017

**Citation:** Shamseldien R, Shehabeldien A, Hendam H. Grading System for Cranial Suture Closure in Early Craniosynostosis. Med - Clin Res & Rev. 2017; 1(1): 1-5.

### ABSTRACT

**Objective:** Thirty patients early diagnosed within the first six months of age as primary craniosynostosis. Were operated by early suture release surgery endoscopic assisted suturectomy in neurosurgery department in Shebin Elkom Teaching hospital (2011- 2016). The studied group 16 females 14 males all have primary craniosynostosis. 9 Brachycephaly, 7 scaphocephally, 4 anterior plagiocephaly, 4 trigonocephaly, 2 posterior plagiocephaly and 4 oxycephaly. 63.3% of patients presented with deformity alone. Other clinical presentations as manifestations of increased intracranial pressure (vomiting, irritable crying, and fits) and delayed milestones plus deformity was 30%, 6.7% respectively. The 3D CT volume rendering technique of all of them retrospectively studied, and Ectocranial skull suture closure grading system of Meindl and Lovejoy applied to 3D skull of the studied group as it simulate real time one. Of all patients 38 sutures was affected. After application of proposed grading 10 sutures G1, 16 sutures G2 and 12 sutures G3. Of coronal sutures 6 G1, 13G2, and 4G3. Of lambdoid sutures 2G1 and 1G3. Of metopic sutures 5 are G3. And of sagittal sutures 2G1, 3G2, and 2G3.

**Conclusion:** Application of ectocranial skull suture closure grading system to 3D skull in early cases of primary craniosynostosis will help in precise diagnosis and surgical decision, as it demonstrate the degree of affected suture from single bony bridge that restrict or arrest suture growth in mild cases to completely obliterated one.

### Keywords

Craniosynostosis, 3DCT, Grading system.

### Introduction

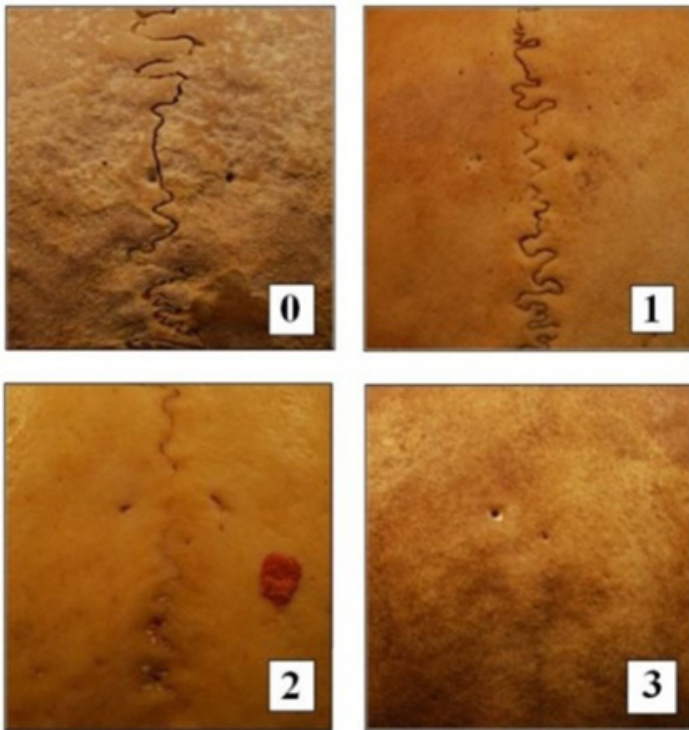
Craniosynostosis is the premature closure of calvarial sutures. Primary craniosynostosis is due to abnormalities of skull development, whereas secondary craniosynostosis results from failure of brain growth and expansion [1]. It has an estimated frequency of 0.4 of 1000 persons. Approximately 80 to 90% of cases involve isolated suture, in which the sagittal suture is the commonest (55%), followed by the coronal (20%), lambdoid (5%), and metopic (5%) sutures. The remaining cases are a part of a recognized syndrome such as Crouzon or Apert [2]. There is a 7% chance of increased intracranial pressure with one suture synostosis and the risk increased when multiple suture are involved. In cases of multiple suture craniosynostosis the incidence of increased intracranial pressure can be as high as

62% [3]. Plain skull radiographs were the first method used to radiologically evaluate patients with suspected craniosynostosis. At least four views are necessary to examine all sutures. If one suture in particular raises concern, a tangential view of this area is useful, particularly if a bony ridge is palpable. It is important to evaluate the entire length of each suture because only a small segment may be involved and profoundly delay or arrest growth. The signs of craniosynostosis on plain radiography include bony bridging across the suture that produces beaking or heaping up of bone; sclerosis, straightening and narrowing of the suture and loss of suture clarity [4]. The introduction of computed CT revolutionized the imaging of craniosynostosis. This modality not only depicts the osseous pathology exquisitely but also allows for the detection of associated intracranial abnormalities, including hydrocephalus and brain developmental anomalies, such as agenesis of the corpus callosum [5]. In addition, CT can identify alternative causes for asymmetric cranial morphology, such as

brain hemiatrophy and chronic subdural collections [6]. A blinded study performed on a relatively small cohort (25 infants) reported that the sensitivity of CT with 3D surface-rendered reconstructions to be in the range of 96–100%. CT reviewer experience and image quality play an important role in the achieved diagnostic performance. The sensitivity and specificity is 96.4 and 100%, respectively, for experienced CT reviewers, while less experienced CT reviewers had a significant drop in specificity of the test to 83%, and 3D shaded rendering of the skull was superior to the combined information from 2D CT and plain radiography [7]. There is a report of an overall sensitivity of 100% for CT diagnosis of synostosis in 12 infants [8].

### Patients and Methods

This is a retrospective analytical study of 3D CT volume rendering technique of thirty patients, diagnosed as non syndromic primary craniosynostosis. All of them were operated by early suture release surgery endoscopic assisted suturectomy in neurosurgery department in Shebin Elkom Teaching hospital (2011- 2016). In this work we apply the Mindle and Lovejoy grading system (Figure 1) for cranial suture closure to 3D CT volume rendering technique done for the patients as it show the human skull as the real one.



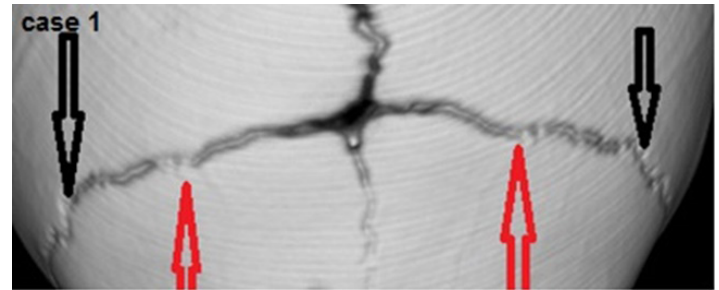
**Figure 1:** Vault suture closure stages. Illustration of degrees of closure for sagittal suture at obelion. Texas State Donated Skeletal Collection.

So by this mean we can evaluate the stenosed suture precisely in early types of craniosynostosis instead of broad terms complete closure versus incomplete as in this category of patients single or multiple small islands of closure may not evident radiologically while the deformity is clinically evident by any degree. Score of ectocranial suture closure according to Meindl and Lovejoy 1985:

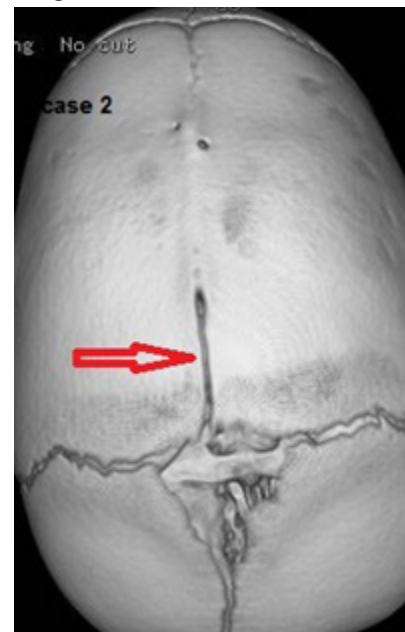0 open; there is no evidence of any ectocranial closure, 1 minimal closure; the score is assigned to any minimal to moderate closure, from single bony bridge to about 50% synostosis, 2 significant closure; there is marked degree of closure but some portion still not completely fused, and 3 complete obliteration; the site is completely fused.

### Cases

**Case 1:** Male child 4months old, brachycephalic head show bicoronal upper 1/3 bony bridge (red arrow) and lower third closed (black arrow), according to ectocranial suture closure by Meindl and Lovejoy of both coronal sutures G 1.

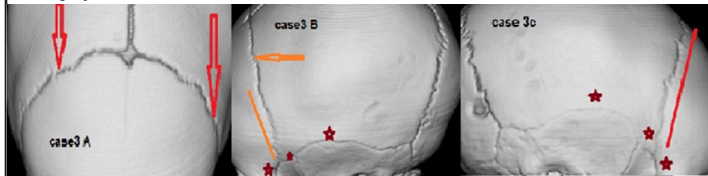


**Case 2:** Male child 2months old, scaphocephalic head show; marked closure of sagittal suture except anterior 1/3 (red arrow) while no evidence of closure at bicoronal, anterior fontanel, or metopic sutures. According to ectocranial suture closure by Meindl and Lovejoy of sagittal suture G 2.

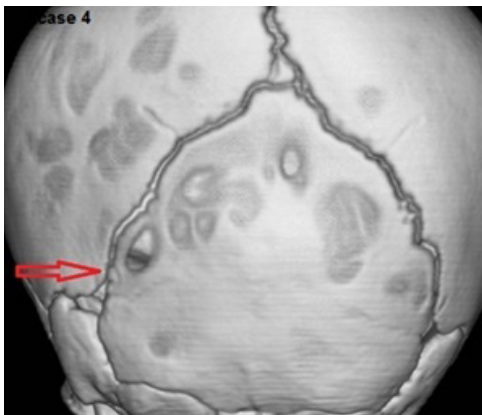


**Case 3:** Female child 6th months old clinically presented by brachycephalic deformity. A: show still open sagittal suture narrow anterior fontanel marked closure of Rt coronal moderate Lt coronal (red arrow show bilateral bony bridges). B: show obliterated lower 1/2 of Lt coronal (orange line), obliterated pterion, sphenofrontal, superior temporal (red star) and still open lambdoid suture. C: show almost obliterated Rt coronal (red line) obliterated pterion, sphenofrontal, superior temporal (red star) and still open lambdoid

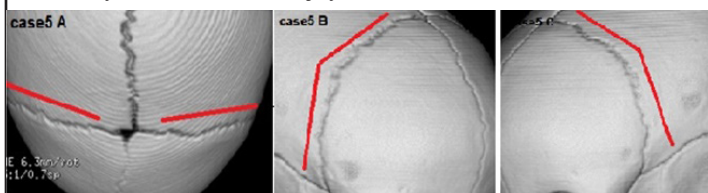
suture. According to ectocranial suture closure by Meindl and Lovejoy Rt coronal G 2 and Lt coronal G1.



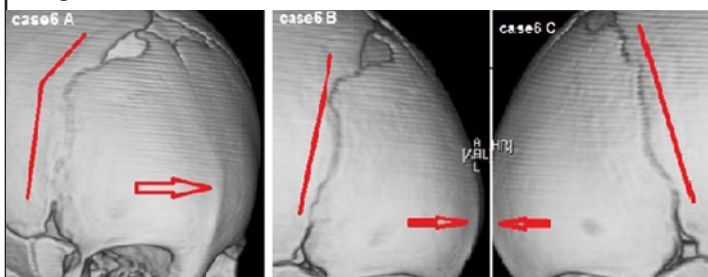
**Case 4:** Male patient 2 months old presented with Lt posterior plagiocephaly show; only single bony bridge at lower part of Lt lambdoid suture (red arrow), while other sutures still open. Also associated marked skull lacunae. According to ectocranial suture closure by Meindl and Lovejoy Lt lambdoid suture G1.



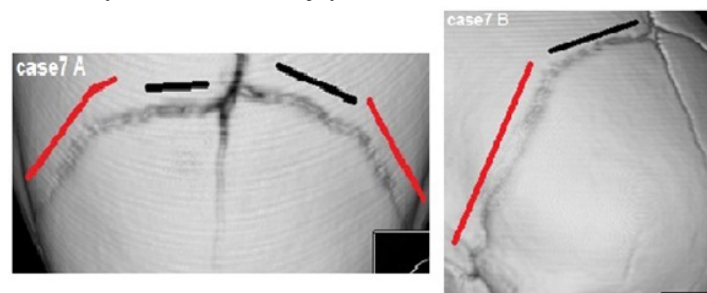
**Case 5:** Male child 6th months old clinically presented by brachycephalic deformity. A show still open sagittal suture narrow anterior fontanel marked closure of bicoronal sutures. B and C show markedly obliterated both Rt (middle view) and Lt (lower view) coronal sutures (red lines). According to ectocranial suture closure by Meindl and Lovejoy bicoronal sutures G 2.



**Case 6:** Female patient 4months old presented with trigonocephalic deformity show; complete metopic obliteration with bone bridging as seen in upper view (red arrow). Moderate closure of both coronal (red lines) still open upper coronal segments and sphenofrontal bilaterally. According to ectocranial suture closure by Meindl and Lovejoy bicoronal sutures G1 as the synostosis up to 50% while metopic suture G3.



**Case 7:** Female child 4months old, brachycephalic deformity narrow anterior fontanel show; marked obliteration of bicoronal sutures, complete at lower 1/2 (red lines), and multiple bony bridges at upper 1/2 (black lines). According to ectocranial suture closure by Meindl and Lovejoy bicoronal sutures G2.



### Result

The studied group 30 patients 16 females 14 males all have primary craniosynostosis. 9 Brachycephaly, 7 scaphocephaly, 4 anterior plagiocephaly, 4 trigonocephaly, 2 posterior plagiocephaly and 4 oxycephaly. 63.3% of patients presented with deformity alone. Other clinical presentations as manifestations of increased intracranial pressure (vomiting, irritable crying, and fits) and delayed milestones plus deformity was 30%, 6.7% respectively. Of all patients 38 sutures was affected. After application of proposed grading 10 sutures G1, 16 sutures G2 and 12 sutures G3. Of coronal sutures 6 G1, 13G2, and 4G3. Of lambdoid sutures 2G1 and 1G3. Of metopic sutures 5 are G3. And of sagittal sutures 2G1, 3G2, and 2G3.

Age	Mean		4.4
	± SD		1.8
Gender	F	No	16
		%	53.3%
	M	No	14
		%	46.7%

**Table 1:** demonstrate the age and sex distribution of the studied group.

	Brachycephaly		Anterior plagiocephaly		Oxycephaly		Posterior plagiocephaly		scaphocephaly		Trigonocephaly		total	
	No	%	No	%	No	%	No	%	No	%	No	%		
sex	M	2	22.2	0	0	3	75	2	100	7	100	1	25	15
	F	7	77.8	4	100	1	25	0	0	0	0	3	75	15
Total	No	9		4		4		2		7		4	30	
	%	30%		13.3%		13.3%		6.7%		23.4%		13.3%	100%	

**Table 2:** Distribution of deformity in relation to sex among studied group.

	%	No
Deformity alone	19	63.3
Deformity plus manifestation of increased ICP	9	30
Deformity plus delayed milestones	2	6.7



**Table 3:** This table demonstrates that the majority of cases of the studied group presented with deformity alone 63.3%. Other clinical presentations as manifestations of increased intracranial pressure (vomiting, irritable crying, and fits) and delayed milestones plus deformity was 30%, 6.7% respectively.

		No	%
Affected Sutures	bicoronal	20	52.6%
	bilambdoid	2	5.3%
	lt lambdoid	1	2.6%
	lt unicoronal	1	2.6%
	Metopic	5	13.2%
	rt unicoronal	2	5.3%
	sagittal	7	18.4%
	Total	38	100.0%

**Table 4:** Demonstrate the distribution of affected sutures.

		No	%
Grade of Closure on 3D	G1	10	26.3%
	G2	16	42.1%
	G3	12	31.6%
	Total	38	100.0%

**Table 5:** Demonstrate the distribution of affected sutures according to proposed grading.

			G1	G2	G3	Total
Affected Sutures	bicoronal	No	6	12	2	20
		%	60.0%	75.0%	16.7%	52.6%
	bilambdoid	No	1	0	1	2
		%	10.0%	0.0%	8.3%	5.3%
	lt lambdoid	No	1	0	0	1
		%	10.0%	0.0%	0.0%	2.6%
	lt unicoronal	No	0	1	0	1
		%	0.0%	6.3%	0.0%	2.6%
	Metopic	No	0	0	5	5
		%	0.0%	0.0%	41.7%	13.2%
	rt unicoronal	No	0	0	2	2
		%	0.0%	0.0%	16.7%	5.3%
	sagittal	No	2	3	2	7
		%	20.0%	18.8%	16.7%	18.4%
	Total	No	10	16	12	38
		%	100.0%	100.0%	100.0%	100.0%

**Table 6:** Demonstrate the relation of affected sutures individually and the proposed grading, (e.g. there are 20 affected coronal sutures, 6 of G1, 12 of G2 and 2 of G3).

## Discussion

Discrepancy in the grading of Craniosynostosis, in spite of the presence of cranial deformity, that reflects the severity of ossification and stenosis in affected sutures exist. The importance of evaluating the entire length of each suture is highlighted [4]. A small segment may be involved and profoundly delay or arrest cranial growth.

Mild degree of suture involvement is not always diagnosed at birth [9]. So, accurate grading will provide proper assessment of affected sutures and its early management. This study includes thirty patients, sixteen females and fourteen males were presented with non syndromic primary craniosynostosis. Operated upon for sutulectomy as early simple release surgery for craniosynostosis with a mean age of 4.4 months (standard of deviation: 1.8). The early interference is encouraged by some authors as early timing of surgery helps prevent permanent skull and brain deformity and has the best cosmetic result, also surgery is best performed in early infancy because; most brain growth occurs in the first year of life. The deforming vectors of the continually growing brain result in progression of the deformity with increasing age [10,11].

The pattern of deformity distribution among male and female cases in this work revealed that the brachycephalic (bilateral coronal) 77% and anterior plagiocephalic (unilateral coronal) 100% deformities were common in female gender. Scaphocephalic deformity (sagittal craniosynostosis) 100% was common in male gender. These finding were coincident to the main stream results of literatures, where sagittal craniosynostosis, is more frequent in males (70%-90% of cases), coronal craniosynostosis has a slightly higher incidence among females (55%-70%), and Bilateral involvement of the coronal suture showed much female predilection, with 76% of bicoronal craniosynostosis occurring in females, as compared with the more modest 54% female majority in unicoronal craniosynostosis [12].

There is a 7% chance of increased intracranial pressure with one suture Craniosynostosis that rises to 62% with multiple suture involvement [3]. This chance of increased intracranial pressure detected it in 20% of nonsyndromic single suture craniosynostosis patients [13]. And this coincident to the result of this studied group, where 30% of patients presented with manifestations of increased intracranial pressure in the form of unexplained vomiting, irritable cry, fits and optic atrophy. In the studied group the affected sutures were 38 that include 23 coronal, 7 sagittal, 5 metopic and 3 lambdoid. After application of the proposed grading (Mindle and Lovejoy grading system for ectocranial suture closure 9) to 3D CT skull volume rendering technique, the distribution of affected sutures were; completely obliteration whole length G3, 12 sutures and significantly closed more than 50% G2, 16 sutures and less than 50% obliteration G1, 10 sutures. Among the coronal sutures six G1, thirteen G2 and four G3. Among the sagittal sutures tow G1, three G2 and tow G3.

All metopic sutures were five G3. Lambdoid sutures tow G1 and one G3. published series of 243 infants under 12 months of age who underwent three dimensional CT for quantitative analysis of developmental process of cranial suture in Korean infants utilized a similar grading classification, four suture closure grades (grade 0=no closure along the whole length, grade 1=partial or intermittent closure, grade 2=complete closure with visible suture line, grade 3=complete fusion (ossification) without visible suture line [14]. They aimed at understanding the pattern of sutural development in normal infants, and assist in diagnosis the of skull deformities

such as craniosynostosis, skull fracture or increased intracranial pressure. Our proposed grading is similar, but the studied group were already have primary craniosynostosis within the first six months of age while the other series were normal infants up to 12 months of age, also this study aimed at early detection and early management [15,16].

## Conclusion

The utilization of this grading system for craniosynostosis will help in precise diagnosis and early surgical decision that is important to apply for the early cases to prevent secondary neural insult, especially in primary craniosynostosis where the pathology is away from brain itself. It demonstrates accurately the degree of suture involvement from single bony bridge to a completely obliterated one. So, there is no chance to miss even mild form of the disease.

## References

1. Behrman RE, Kuelman R, Jenson H. Craniosynostosis, in Kliegman R (edn): Nelson Textbook of Pediatrics, ed 16. Philadelphia: WB Saunders. 2000; 1831-1832.
2. Aleck K. Craniosynostosis syndromes in the genomic era. Semin Pediatr Neurol J. 2004; 11:256-261.
3. Renier D, Lajeunie E, Arnaud E, et al. Management of craniosynostosis. Childs Nerv Syst. 2000; 16: 645-658.
4. Aviv RI, Rodger E, Hall CM. Craniosynostosis. Clin Radiol J. 2002; 57: 93-102.
5. De León GA, de León G, Grover WD, et al. Agenesis of the corpus callosum and limbic malformation in Apert syndrome. Ach Neurol J. 1987; 44: 979-982.
6. Abrahams JJ, Eklund JA. Diagnostic radiology of the cranial base. J Clin Plast Surg. 1995; 22: 373-405.
7. Vannier MW, Pilgram TK, Marsh JL, et al. (1994): Three-dimensional analysis of mandibular growth and tooth eruption. Am J Neuroradiol. 1994; 15: 1861-1869.
8. Agrawal D, Steinbok P, Cochrane DD. Reformation of the sagittal suture following surgery for isolated sagittal craniosynostosis. J Child's Nerv Syst. 2006; 22: 375-378.
9. Panchal J, Uttchin V. Management of craniosynostosis. Plast Reconstr Surg. 2003; 111: 2032-48.
10. Barone CM, Jimenez DF. Endoscopic craniectomy for early correction of craniosynostosis. Plast Reconstr Surg J. 2000; 104: 1965 -1973.
11. Gault DT, Renier D, Marchac D, et al. Intracranial pressure and intracranial volume in children with craniosynostosis. Plast Reconstr SurgJ. 2005; 90: 377.
12. Sloan GM, Wells KC, Raffel C, et al. G: Surgical treatment of craniosynostosis: outcome analysis of 250 consecutive patients. Pediatrics. 1997; 100: E2.
13. Tamburrini G, Caldarelli M ML, Santini P, et al. Intracranial pressure monitoring in children with single suture and complex craniosynostosis: a review. Childs Nerv Syst. 2005; 21: 913-921.
14. Sook Young Sim, Soo Han Yoon, Sun Yong Kim. Quantitative Analysis of Developmental Process of Cranial Sutures in Korean Infants. J Korean Neurosurg Soc. 2012; 51: 31-36.
15. Meindl RS, Lovejoy CO. Ectocranial suture closure: a revised method for the determination of skeletal age at death based on the lateral anterior sutures. Am J Phys Anthropol. 1985; 68: 57-66.
16. Thomas GP, Wilkie AO, Richards PG. FGFR3 P250R mutation increases the risk of reoperation in apparent 'nonsyndromic' coronal craniosynostosis. J Craniofac Surg. 2005; 16: 347-354.